

Submitted to The Journal of Practical Periodontics and Aesthetic Dentistry for the ANTHOLOGY edition.

July 3, 2003

## **The Interproximal Height of Bone: A Guidepost to Esthetic Strategies and Soft Tissue Contours in Anterior Tooth Replacement**

### **Authors:**

#### **Henry Salama, DMD**

Clinical Assistant Professor, Department of Periodontology, University of Pennsylvania, Philadelphia, Pennsylvania; Private Practice, Atlanta, Georgia

#### **Maurice A. Salama, DMD**

Assistant Clinical Professor, Department of Periodontology, Medical College of Georgia School of Dentistry; Private Practice, Atlanta, Georgia

#### **David A. Garber, DMD**

Clinical Professor, Department of Periodontics; Medical College of Georgia School of Dentistry; Private Practice, Atlanta, Georgia

#### **Pinhas Adar, MDT**

Private practice, Oral Design Center, Atlanta, Georgia

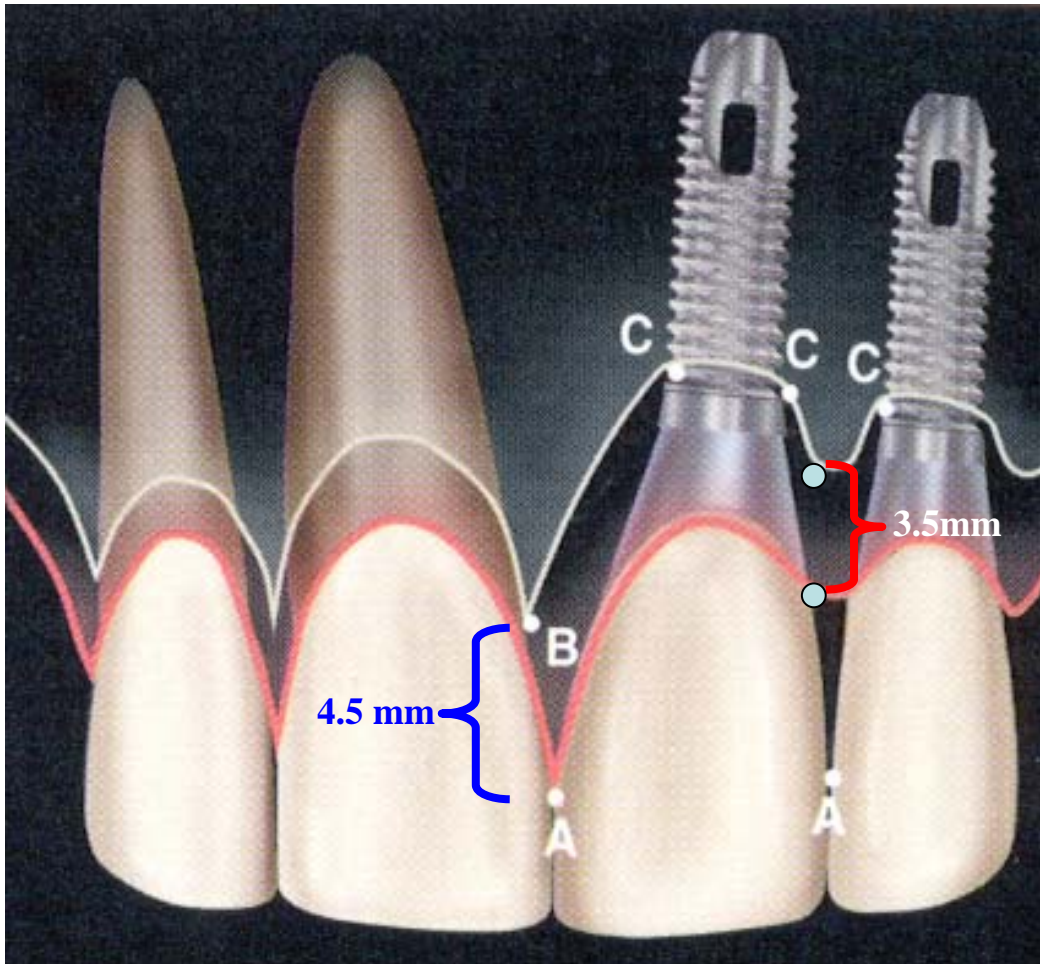
### **Review and follow-up to the 1998 article**

The literature, through the concept of the “biological width,” outlines the *minimum* soft tissue dimension that is physiologically necessary to protect and separate the osseous crest from a healthy gingival margin surrounding teeth and the peri-implant environment. This approximately 3mm minimum zone is comprised of roughly 1mm for the connective tissue zone immediately adjacent to the osseous crest, 1mm for the junctional epithelium and 1mm for sulcular epithelium. In contrast to assuring the minimum biological dimensions, the therapeutics of soft tissue esthetics, by necessity, are more concerned with developing the *maximum* achievable and maintainable soft tissue dimensions.

Clinicians have long had access to an array of effective surgical techniques for maximizing muco-gingival and ridge dimensions through the utilization soft tissue and osseous grafts<sup>1-5</sup>. The regeneration of interproximal papillae deficiencies, however, has not enjoyed the same degree of success. Tarnow et al. (1992)<sup>6</sup> and Salama et al. (1998)<sup>7</sup> have explained this discrepancy by illuminating the key role that the underlying osseous architecture plays in predicting and guiding overlying interproximal soft tissue contours. The subsequent five years since the publication of

the 1998 article has only re-emphasized the relevance of the therapeutic principles suggested.

**Figure 1: Only the most coronal interproximal peak of bone and its overlying tissue dimension was included in the data collection and analysis. It is this measurement that has the most clinical relevance in prognosticating soft tissue esthetics.**



In preparation for this addendum to the original 1998 article, the authors have added new clinical data collected over the past five years. In addition, the original data was re-analyzed to create consistency with the measurement methodology utilized in an upcoming multi-center study<sup>8</sup>. Instead of including two measurements at each opposing base of an individual interproximal site (Figure 1: points B & C), whether tooth, implant or pontic, only the most coronal peak of bone and its overlying tissue dimension was included in the new chart (Figure 1: distance between A & B). The combined data and new analysis has allowed for the development of a simplified reference chart for clinicians planning anterior tooth replacement (Chart 1). The data suggests the existence of a “predictably achievable papilla height”, defined as the maintainable papilla length in the maxillary anterior

sextant as measured from the most coronal IHB for all tooth replacement permutations.

**Chart 1: Predictably achievable interproximal soft tissue dimensions measured from the most coronal IHB. (note: measurements rounded to nearest half millimeter for clinical relevance and utilization)**

<b>CLASS</b>	<b>Restorative Environment</b>	<b>Proximity Limitations</b>	<b>Vertical Soft Tissue Limitations</b>
<b>1</b>	<b>Tooth-Tooth</b>	<b>1</b>	<b>5 mm</b>
<b>2</b>	<b>Tooth-Pontic</b>	<b>N/A</b>	<b>6.5 mm</b>
<b>3</b>	<b>Pontic-Pontic</b>	<b>N/A</b>	<b>6.0 mm</b>
<b>4</b>	<b>Tooth-Implant</b>	<b>1.5mm</b>	<b>4.5 mm</b>
<b>5</b>	<b>Implant-Pontic</b>	<b>N/A</b>	<b>5.5 mm</b>
<b>6</b>	<b>Implant-Implant</b>	<b>3mm</b>	<b>3.5 mm</b>

**Summary 2003:**

In conclusion, the data clearly demonstrates that predictable soft tissue vertical dimensions in the optimized maxillary anterior interproximal site cannot be represented by one measurement or number. Indeed, the dimensions are effected by and differ significantly by the various possible combinations of tooth, implant and pontic which may border a specific interproximal site. In addressing tooth replacement challenges in the anterior region, the authors utilize the data represented in the accompanying chart as the bedrock for designing treatment plans that ensure the development of restorative esthetic profiles which integrate predictable interproximal papillae dimensions. In addition, this data can be utilized as a standardized and effective communicating tool among team members.

References:

1) Langer B, Calagna L: The subepithelial connective tissue graft. J Prosth Dent: 1980;44:363-367

- 2) Abrams L. Augmentation of the deformed residual edentulous ridge for fixed prosthesis; *Compend Contin Educ Dent*. 1980;1:205-213
- 3) Miller PD. Root coverage using a free soft tissue autograft following citric acid application. I. Technique: *Int J Perio & Rest Dent*; 1982;2:1:65-70.
- 4) Seibert J, Lindhe J. Esthetics and Periodontal Therapy. In: Lindhe J (ed). *Textbook of Clinical Periodontology*, ed 2. Copenhagen: Munksgaard, 1989:477-514
- 5) Tinti C, Vincenzi G, Cocchetto R. Guided Tissue Regeneration in mucogingival surgery. *J of Perio*, 1993;64:1184-1191.
- 6) Tarnow DP, Magner AW, Fletcher P: The effect of distance from the contact point to the crest of bone on the presence or absence of the interproximal dental papilla: *J of Perio*: 1992;63:12:995-996
- 7) The Interproximal height of Bone: A Guidepost to Esthetic Strategies and Soft Tissue Contours in Anterior Tooth Replacement: Salama H, Salama MA, Garber DA, and Adar P: 1998 *Practical Periodontics and Aesthetic Dentistry*;
- 8) Tarnow DP, Elian N, Fletcher P, Froum S, Magner A, Cho S-C, Salama MA, Salama H, and Garber DA: 2003; accepted for publication; *J of Perio*.